

Five Years Clinical Follow up Bone Regeneration with CaP BioceramicsClemencia Rodríguez¹, Alain Jean², Sylvia Mitja³ and Guy Daculsi^{2,4,a}¹Dental Faculty of Bogota, Nacional University of Colombia, Colombia²University of Nantes, ERT 1051, Dental Faculty, France³Biomatlante SAS, Vigneux de Bretagne, France⁴INSERM CIC, Bordeaux Hospital, France^aguy.daculsi@univ-nantes.fr**Keywords** : biphasic calcium phosphate, clinical follow up, bone regeneration, dental filling

Abstract. To overcome autograft use for dental implantation, it is important to prevent bone loss after tooth extraction or to restore alveolar bone level after pathological diseases. Biphasic calcium phosphate (BCP), mixture of HA and β TCP, have proven its performance in orthopaedic, while few studies have been reported in dentistry. We reported 5 years clinical follow up on bone regeneration after immediate dental root filling. MBCP 60/40 and MBCP 20/80 (Salvin Orastruct[™])* are biphasic CaP intimate mixture of HA/TCP 60/40 and 20/80; with interconnected macroporosity and microporosity. Forty cases have been distributed in two groups for alveolar pocket filling. Seven cases without filling are used as control. XRay at 0, 3, 6, 12 months and 5 years follow up for some patients were performed. In all the 40 cases, radioopacity of the implantation area decreases on time, indicating resorption and bone ingrowths at the expense of the two bioceramics. No difference in the resorption kinetics appeared on XRay. After 1 year, the implantation area looks as physiological bone and is maintained on time. The newly formed bone is preserved after 5 years contrarily to the controls cases (without filling) where we observed decrease of 2 to 5 mm. This study demonstrated that immediate filling of alveolar pocket after tooth extraction is a preventive method of the jaw bone resorption. After long term (other one year) resorption and bone ingrowth were demonstrated for both micro and macroporous biphasic calcium phosphate with two different HA/TCP ratio.

Introduction

Among the available materials used for preimplant bone reconstruction, autologous bone is currently the goldstandard because it is a source of osseous matrix, cells, and growth modulating molecules [1]. However, second site surgery is required to harvest the bone material, which makes the initial operation more complicated. To overcome the autograft limits, many substitution biomaterials have been developed. Materials from human and animal origin have the disadvantages of limited supply and potential risk of cross contamination.[2,3]. Consequently, synthetic products were developed [4]. Generally Biphasic calcium phosphate (BCP), an intimate mixture of hydroxyapatite (HA) and β tricalcium phosphate (β TCP) [5] or pure β TCP was proposed in dentistry as reference for synthetic materials. BCP offers a great potential for bone reconstruction since it has a chemical composition close to biologic bone apatites. Biphasic calcium phosphate, has already proven its efficiency as bone substitution material in different human clinical applications [6,11] however there are only few published clinical data on long term follow up. Xenograft as BioOss[®] derived from bovine bone was largely used in dentistry in spite of animal origin material. BCP offers the potential for bone reconstruction since it has a chemical composition close to biologic bone apatites. The concept of HA and β TCP mixture (BCP) with different HA/ β TCP ratio, demonstrated the bioactivity of these bioceramics. Subsequently, focussed studies on BCP led to the significant increase in manufacture and use of BCP as bone substitute materials for dental and orthopaedic applications and for tissue engineering matrix.

The aim of the present study was to assess the MBCP™ with two different HA/TCP ratio 40/60 and 20/80 (Salvin Orastruct™)* in dentistry. Five years clinical follow up, bone regeneration with immediate filling of dental socket have been reported.

Materials and Methods

MBCP® 60/40 and MBCP 20/80 (Salvin Orastruct™)* are biphasic CaP nanoscale mixture of HA/TCP 60/40 and 20/80; with similar interconnected macroporosity and microporosity (70% total porosity with 75% of macropores of 300 to 600µm and 25% of micropores). The forty cases from 27 patients were followed up after tooth extraction and immediate socket filling. Nine males and 18 females with an age range from 24 to 60 were selected. The forty cases were dispatched within 2 groups, one for alveolar filling and the other group as control. Seven cases were not filled and selected as control after surgical extraction. After mucosa preparation, the sockets were filled with granules of 0.5 to 1 mm mixed with blood. Xray at 0, 3, 6, 12 months and 3 to 5 years were performed. Ten biopsies were realized before implantation and processed for histomorphometry and micro CT. Briefly, under local anesthesia biopsies were performed using a cylindrical trocar and irrigation, 3mm in diameter, bone biopsies were harvested. The biopsies were fixed in a formalin solution, dehydrated with graded alcohol and embedded in GMMA for histological analyses. Before sectioning process using diamond saw and a hard tissue microtome, the blocks were analysed with microCT (Skyscann 1072). On thicker sections (100µm), SEM observations using backscattering electron (BSE) combined to Image analysis were used for bone ingrowth and bioceramic resorption evaluation. Light microscopy was performed on 7 µm thick section (Movat's pentachrome staining) and polarized light microscopy on thick section of 100µm without staining.

Results

For all the 40 cases, radio-opacity of the implantation area decreased on time indicating resorption and bone ingrowth at the expense of the two bioceramics. No statistical difference in the resorption kinetics of resorption were observed on X-rays between the two BCP ratio. After 1 year, the implantation area looks as physiological bone and was maintained on time.

The high of the bone regeneration level has been the same after 5 years. The newly formed bone is preserved contrarily to the controls cases (without filling) were decreased from 2 to 5 mm.

In light microscopy, bone ingrowth was observed into all the biopsies. Bone trabeculae appeared in both samples between the residual granules and large osteoconduction was noticed in close contact to the granules (fig2). High standard deviation was observed for the resorption and bone ingrowth in the MBCP (Salvin Orastruct™)*, some samples are fully resorbed after 31 months, others revealed residual granules as MBCP 60/40 (Fig 2 b and c). However more resorption on time with significant difference was measured for MBCP 20/80 (Salvin Orastruct™)* when time of implantation and residual granules were compared.

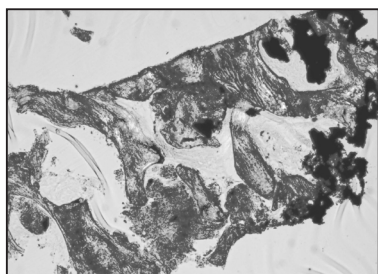


Fig2a :
MBCP 60/40
56 months

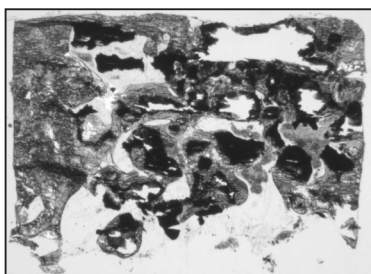


Fig2b:
MBCP 20/80 (Salvin Orastruct™)*
36 months

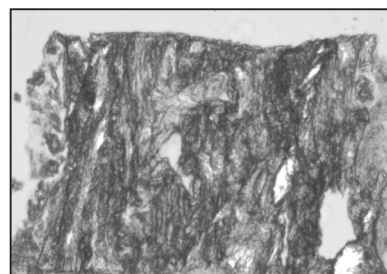


Fig2c:
MBCP 20/80 (Salvin Orastruct™)*
31 months

The density of the granules decreased on time after implantation traducing changes in the mineral content (re-absorption of Ca and Phosphate ions, and precipitation of biological apatite. This phenomenon was largely known and published for Biphasic calcium phosphate [12,13]. In all

samples, few woven bone was observed; the newly formed bone is well mineralized and essentially with a lamellar architecture. Evidence of bone remodelling was observed in all sample. Not yet resorbed granules of both MBCP HA/TCP ratio were entirely covered by lamellar bone, and macropores were filled with architected bone.

Micro CT confirms the bone ingrowth and bone architecture at the expense of the residual bioceramics. Also the density of the granules appears lower after implantation (fig 3A and B). Quantitative analyse of the newly formed bone and residual ceramic was performed in Micro CT. Table 1 summarize the data, percentage are related to the volume occupied:

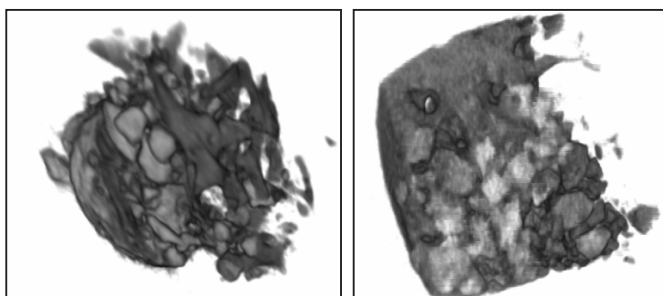


Fig 3: A. MBCP 60/40

B. MBCP 20/80
(Salvin Orastruct™)*

Table 1	Implantation time in months Mean \pm SD	% residual Bioceramic	% new bone	Bone marrow
MBCP 20/80 (Salvin Orastruct™)*	34 \pm 7	6.7 \pm 5.1	32.2 \pm 23.9	61.1
MBCP 60/40	56 \pm 3	11.4 \pm 14.8	11.4 \pm 14.8	50.6

Kinetic of resorption between the 2 bioceramics were significant, not for bone ingrowth and bone marrow content.

Histology reported active osteoclast on both BCP granules, with more organized bone in the deep part of the implant comparing to the bottom more close to soft tissue and mucosa.

Discussion

After 4.5 years, average of implantation time, the resorption of the MBCP 60/40 was 78% r and 87% for 20/80 (Salvin Orastruct™)* (difference not significant) and bone ingrowth respectively of 38% and 32%. If a slight difference was observed about resorption and bone ingrowth between the 2 BCP types, no statistical difference can be reported both for resorption and bone ingrowth. Bioceramics resorption (this was not limited to calcium phosphate but for all osteogenic/osteoconductive biomaterials) will be performed when the surface are accessible to macrophages and/or osteoclasts. After bone ingrowth, particularly for high osteogenic/osteoconductive bioceramics, the surface and the macropores are protected by the newly formed bone. The resorption of the bioceramic, will be obtained only with secondary resorption due to bone remodelling of the initial bone formation. Bone remodelling was different from one patient to another, it is sex and age dependant and moreover on the mechanical strengths applied to the bone. This bone physiopathology explains the kinetics of bone ingrowth and bioceramics resorption. The higher percentage of bioceramic resorption was obtained in the early months of implantation, then the resorption process was slower. In spite of long term implantation, it remains bioceramics granules, this could be explained by the bone physiopathology (bone remodelling), which was preserved by high osteogenic bioceramics. In complement, the change of density of the granules observed in microscopy and micro CT, indicates dissolution of CaP at the crystal level and changes in the mineral content by formation of biological apatite [13]. Differences on bone ingrowth between the two types of MBCP are not significant in spite of higher rate of resorption of the MBCP 20/80 (Salvin Orastruct™)*. The higher rate of resorption was due to the higher b-TCP content more soluble than HA. From this study we cannot conclude of different clinical efficiency of MBCP with different ratio.

It is known that pure TCP as RTR® for example have a larger resorption time, but the architecture of the newly formed bone was different, due to difference in bone ingrowth at the expense of the

granules and osteoconduction process. For xenograft like BioOss, no resorption and bone ingrowth was noticed confirmed previous report comparing synthetic calcium phosphate and such bone substitutes [14]. Strategy for bone reconstruction must take in account on one side the kinetic of bioceramics resorption and simultaneous bone ingrowth at the expense of the implants, and on the other side architected regenerated bone, including residual unresorbed granules able to support strengths due to dental implantation.

Conclusion

The immediate filling of alveolar socket after tooth extraction is a preventive method to alveolar bone resorption. After long term (other one year) resorption and bone growth was demonstrated for both micro and macroporous biphasic calcium phosphate with two different HA/TCP ratios (40%-60% and 20% 80%). This data confirm the resorbability on time of MBCP (Salvin Orastruct™)* and the scaffold effect of the HA content and high osteoconduction property. These two properties involved a balance resorption and bone ingrowth at the expense of the micro macroporous bioceramics.

Aknowledgement

We thank Françoise Moreau and Sophie Sourice for their technical assistance and Monika Gottlob for text revision. This work was supported by ERT 1051 from Nantes University

References

- 1 Barboza E.P., Int. J., Periodontics Restorative Dent. 19 (1999) 601
- 2 Al Ruhaimi K.A., Int. J. Oral Maxillofac. Implants 16 (2001) 105
- 3 Vastel L., Lemercier V., Kerboull L., Kerboull M., Rev Chir. Orthop. Reparatrice Appar. Mot. 85 (1999) 164
- 4 Legeros R., Parsons J.R., Daculsi G., Driessens F., Lee D., Liu S.T., Metsger S., Peterson D., Walker M: Bioceramics: Material characteristics Versus in vivo behavior, Ann. N.Y. Acad. Sci. 523 (1988), , 268-271.
- 5 Daculsi G, Laboux O, Malard O, Weiss P. J Mater Sci Mater Med. 2003 Mar;14(3):195-200.
- 6 Daculsi G., Passuti N., Martin S., Deudon C., LeGeros RZ.(1990).. J. Biomed. Mater. Res., 1990, 24, 379-396
- 7 Pascal-Moussellard H., Catonné Y., R. Robert R., Daculsi G., (2007). Proceedings ESB 20, Nantes France
- 8 Gouin, F., Delecrin, J., Passuti, N., Touchais, S., Poirier, P, Bainvel, J.V. (1995). Rev Chir Orthop 81:59-65
- 9 Ransford A.O., Morley T., Edgar M.A., Webb P., Passuti N., Chopin D., Morin C., Michel F., Garin C., Pries D. (1998). " J Bone Joint Surg Br 80(1): 13-18.
- 10 Cavagna, R., Daculsi, G., Bouler, J-M., (1999).. Long term Effects Med Impl 9 : 403-412 23
- 11 Nery E.B., Eslami A., Van S.R., J. Periodontol. 61 (1990) 166
- 12 Daculsi G., LeGeros RZ, Nery E., Lynch K , Kerebel B. (1989). J Biomed Mat Res 23: 883-894
- 13 Daculsi G., LeGeros R.Z., Heugheart M., Barbieux. I. (1990) Calcif Tissue Int 46: 20-27.
- 14 Daculsi, G., Corre, P., Malard, O., Legeros, R., Goyenvalle, E., Key Engineering Materials 2006, 309-311: 1379-1382