

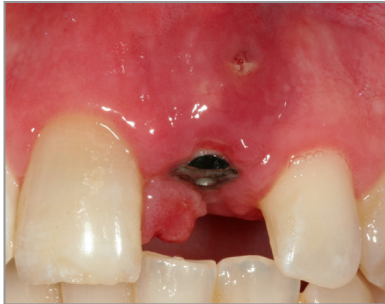**SALVIN**<sup>®</sup>  
**AlloSculpt-3D**<sup>®</sup>

***Demineralized Cortical Allograft Putty  
With Cortical & Cancellous Chips***

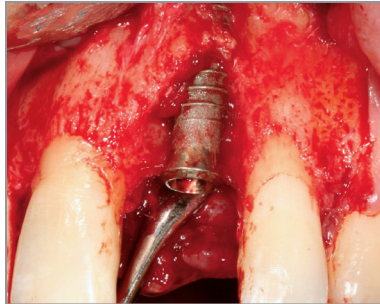
***Dr. Nick Shumaker -  
Case GBR #9***



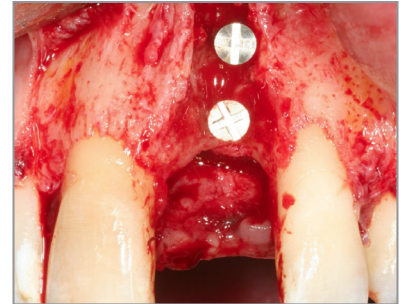
Surgery & Photos:  
Dr. Nick Shumaker  
Periodontist, Fort Collins, CO



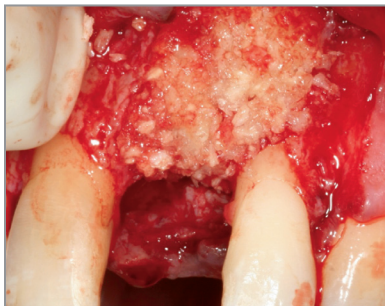**Failing Implant  
With Fistula**



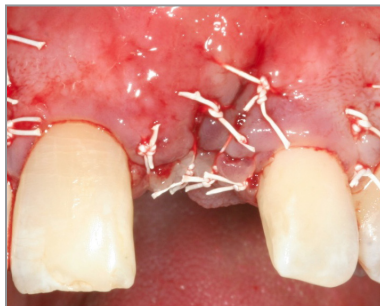**Implant Removal**



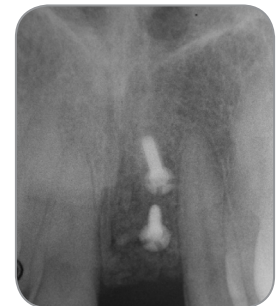**Tenting Screws For  
Horizontal Width**



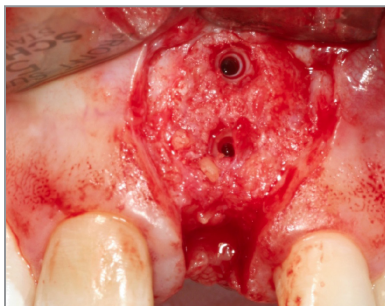
**AlloSculpt-3D Allograft**



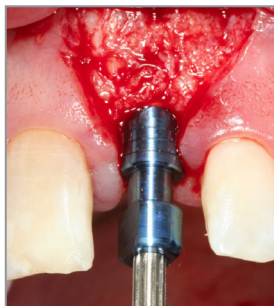
**Primary Closure**



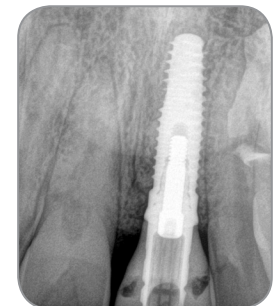**8 Month Post-Op Scan**



**Tenting Screws Removed**



**Implant Site Preparation**



**Final Implant Placement**