

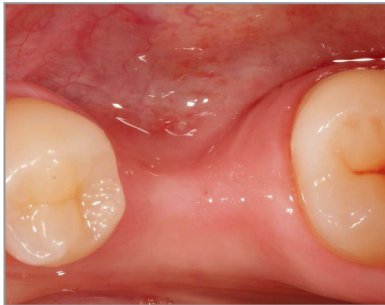SALVIN[®]
AlloSculpt-3D[®]

***Demineralized Cortical Allograft Putty
With Cortical & Cancellous Chips***

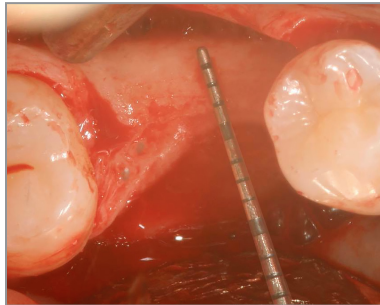
***Dr. Nick Shumaker -
Case GBR #30***



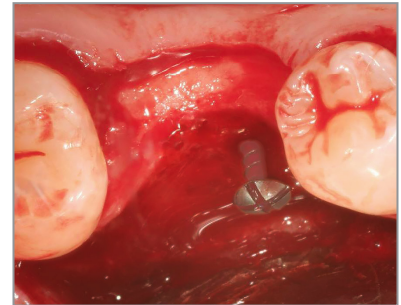
Surgery & Photos:
Dr. Nick Shumaker
Periodontist, Fort Collins, CO



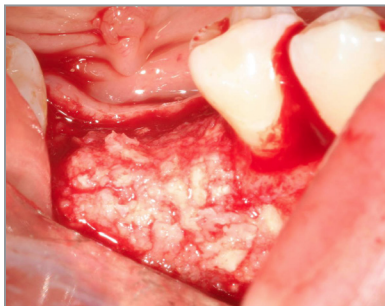
Pre-Op Photo



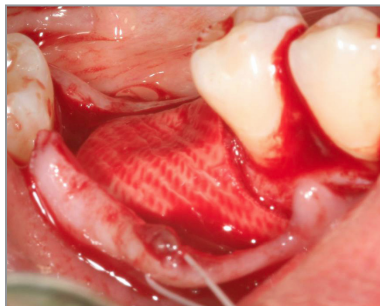
Deficient Ridge Width



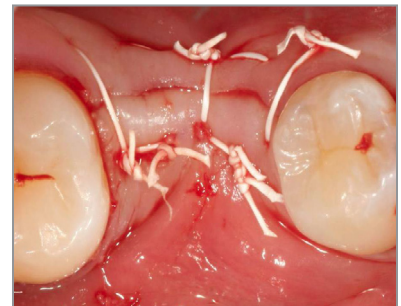
Tenting Screw Placed



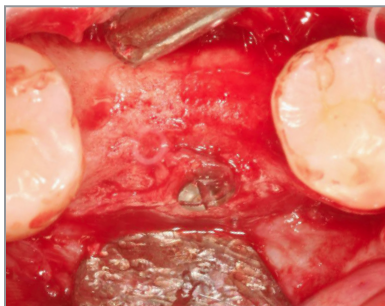
AlloSculpt-3D Allograft



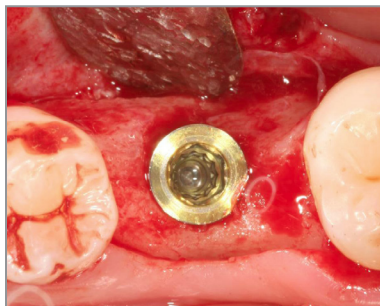
Membrane Over Graft Material



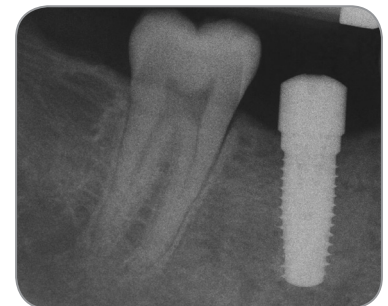Primary Closure



5 Month Post-Op GBR



Implant Placed



Final Radiograph