

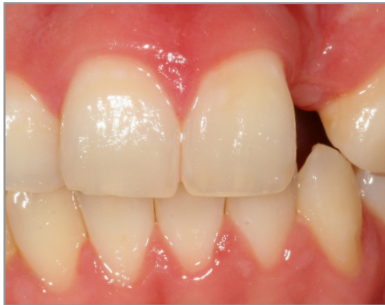SALVIN[®]
AlloSculpt-3D[®]

***Demineralized Cortical Allograft Putty
With Cortical & Cancellous Chips***

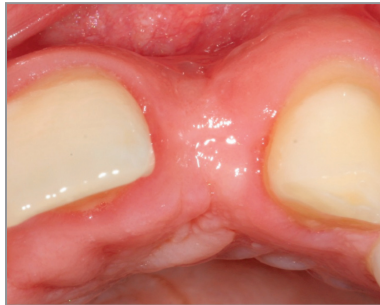***Dr. Nick Shumaker -
Case GBR #10***



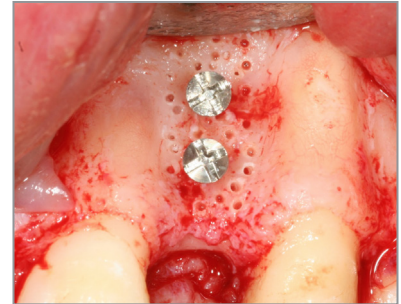Surgery & Photos:
Dr. Nick Shumaker
Periodontist, Fort Collins, CO



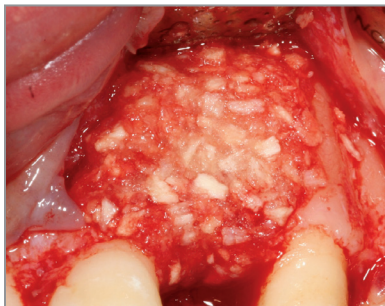
Missing Lateral



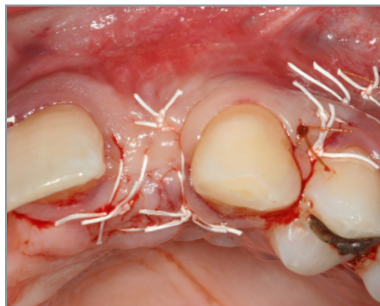Deficient Ridge Width



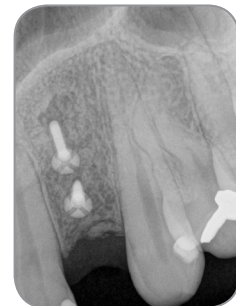**Site Decorticated
Tenting Screws Placed**



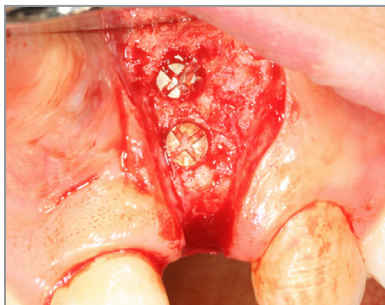AlloSculpt-3D Allograft



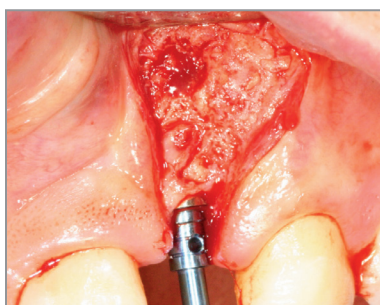
Primary Closure



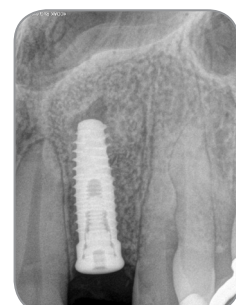5 Month Post-Op Scan



**Reentry At 5 Months
Post-GBR**



Implant Site Preparation



Final Implant Placement